

Teprotumumab, New Era for Thyroid Eye Disease

Main Author

Kale Rohit (rohit.kale242@gmail.com)

B. pharm, M.Tech, Institute of chemical Technology Mumbai

Coauthor

Solanke Shrikant (shrikantsolanke121@gmail.com)

B. pharm, Shivnagar vidyaprasarak mandals college of Pharmacy Malegaon Bk, Baramati

Guided by

Dr. Deshmukh Tejeswini (tejeswini.deshmukhsvpm@gmail.com)

Associate professor Department of Pharmaceutics, Shivnagar vidyaprasarak mandals college of Pharmacy Malegaon Bk, Baramati

Article History

Received: 18/03/2022

Accepted: 15/04/2022

Article ID: RRBB/125

Corresponding Author:

E-Mail:

rohit.kale242@gmail.com

Abstract

Thyroid eye disease is a progression of an autoimmune disease called Graves disease, which majorly affects eye orbits and its muscular tissues. It affects the patients by acting a impact on their quality of life by acting on patients visual balance along with facial disfiguring. In this review paper I will review as the development of monoclonal antibody called teprotumumab for treatment of thyroid eye disease along with its brief mechanism of action.

Keywords: "Teprotumumab", "Hyperthyroidism", "Thyroid eye disease", "Graves disease".

Introduction

Thyroid eye disease though it is due to frequent extra thyroidal manifestation of a autoimmune disease called graves' disease but it may develop in the patients with not having past history of hyperthyroidism . The mild effect of disease also shows impact on a life of patients. The large group of patients experience mild symptoms but only 33% of patients develop into a progressive

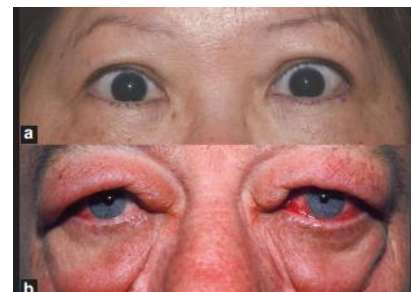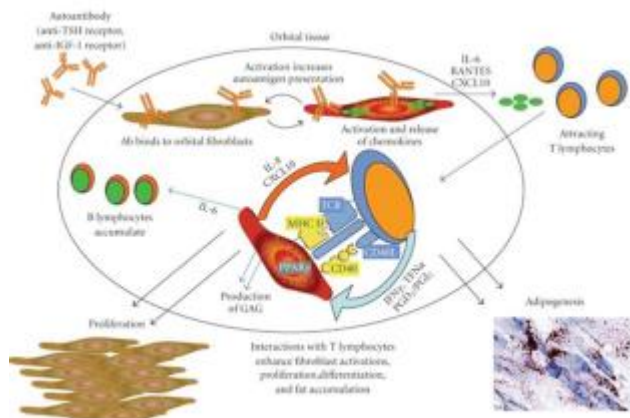
disease. Patients with serious disease may develops into sight threatening complications like (Ting, 2020)swelling and erythema, conjunctival redness and chemosis, and enlargement of the extraocular muscles and the orbital fatty volume resulting in proptosis. The pathophysiology of the thyroid eye disease is not completely known to scientific

community but main role is played by orbital fibroblasts expressing TSH receptors that become activated by TSH receptor auto antibodies. The aim of this review was to analyze the available pathophysiology of disease and the only approved drug teprotumumab and other available spaces for preventive intervention.

Epidemiology of Graves' Ophthalmopathy

A data available from the published studies from United States. Gives information regarding incidence rate of Graves' disease per 100,000 populations per year is 13.9. An important epidemiologic feature of Graves associated thyroid eye disease is linked to cigarette smoking. Pathogenic mechanisms

regarding this is not understood yet but it may be due to smoking might both exert direct irritative effects and contribute to modulate the ongoing immune reactions in the orbital tissues. The disease progress by three steps, the primary stage infection is with no symptoms but progression of disease takes place. Second stage of infection is also asymptomatic but the patients are with elevated levels of thyroid hormone, patients from this stage should stop smoking and also need the treatment regarding hyperthyroidism. The severe disease is in third stage with symptoms like bulging of eye balls, inflammation, pain with redness in affected area



Comparison of a] Normal eye b] TED eye According to Lehmann et al., [18] TED is triggered by binding and activation of orbital fibroblasts by auto antibodies

Conventional Medical Therapies for TED

Diagnosis and treatment of patient with moderate to severe thyroid eye disease is challenging and it requires a team work of both endocrinologists and ophthalmologists.

Conventional treatments used to focus on immune suppression in the active phase in patients with moderate-to-severe disease. Glucocorticoids were the class of drug that was used. Glucocorticoids being preferred by IV over oral administration due to a more favorable safety and efficacy profile since oral administration may undergo a first pass metabolism and the bioavailability of drug

may reduce. Since Glucocorticoids come from steroidal class of a drug called pregnant derivative they have a number of side effects like negative nitrogen balance, muscle wasting, anti insulin effect. To avoid these side effects it was a need to develop a first line therapeutic drug to treat Thyroid

eye disease. Several second line drug therapies also available which includes drugs from anticancer class category like cyclosporine, methotrexate, azathioprine, Like Glucocorticoids; these treatments do not significantly alter long term disease outcomes

Available treatment for TED as function of disease severity and activity

Ocular involvement	Activity	Treatment
Nonsevere	Active	Supportive measures
Nonsevere	Inactive	Supportive measures
Severe	Active	Glucocorticoids, Orbital radiotherapy, Orbital decompression
Severe	Inactive	Orbital decompression, Strabismus surgery, Eyelid retraction surgery

New era of Teprotumumab

(Wiersinga, 2002) Along with insulin like growth factor, fibroblast also plays important role in development of fatty tissues behind eye balls. Fibroblast shows 3-4 times more action in thyroid associated eye disease as compared to normal humans. Teprotumumab binds with high selectivity and affinity to IGF-1R, displacing IGF-1 and resulting in degradation of the receptor, antibody complex. Teprotumumab comes in the form of powder and vial and mixed prior to administration to patients. Teprotumumab is administered by intravenously to patients at an initial dose of 10mg/ kg thereafter 20mg/kg every 3 weeks for 21weeks. The present clinical reports of a remarkable ability of teprotumumab to reverse diplopia and proptosis. Despite the significant reduction in proptosis seen, there was only a modest increase in quality of life in this group. The teprotumumab is considered a choice over Glucocorticoids since it is having selective action and low

side effects than Glucocorticoids. Teprotumumab comes with a side effects like teratogenicity which contraindicates its use in pregnant woman & hyperglycemia which can be reduced by taking with antidiabetic drugs.

Conclusion

Available data study demonstrates effectiveness of Teprotumumab in reversing disease severity and attenuating clinical activity. The safety profile of teprotumumab is extremely favorable, with the majority of adverse events judged as mild. Thus, the drug is poised to become the first-line therapy for Thyroid eye disease.

Provenance and peer review

Not commissioned, internally peer-reviewed.

Sources of funding

This study received no specific grant from any funding agency in the public, commercial, or not-for-profit sectors.

Author contribution

Kale Rohit: Conceptualization, Data study, Visualization, Writing - Original Draft, Writing - review & editing.

Solanke Shrikant: Conceptualization, Data study, Visualization, Writing - Original Draft, Writing - review & editing.

Declaration of competing interest

All authors report no conflicts of interest relevant to this article.

Acknowledgements

All the authors acknowledge and thank their respective Universities and Institutes.

Consent statement/Ethical approval:

Not applicable

References

1. FDA approves first treatment for thyroid eye disease.
2. Smith TJ, et al. Teprotumumab for thyroid-associated Ophthalmopathy. *N Engl J*
3. Douglas RS, et al. Teprotumumab for the treatment of active thyroid eye disease. *N Engl J*
4. Jain D, Mor S, Aggarwal HK, Chhabra P, Jain P. Thyroid association Ophthalmopathy in Hashimoto's thyroiditis: a case report. *Maedica*. 2017; 12: 65-7.
5. Markham A. Teprotumumab: First Approval. *Drugs*.
6. Hwang CJ, Eftekhari K. Teprotumumab for thyroid eye disease. *Int Ophthalmol Clin*. 2020; 60:47-55.
7. Hasselbalch HC. B-cell depletion with rituximab-a targeted therapy for Graves' disease and autoimmune thyroiditis
8. Edwards JC, Leandro MJ, Cambridge G. Lymphocyte depletion therapy in rheumatoid arthritis and other autoimmune disorders.
9. Scott DL, Wolfe F, Huizinga TW. Rheumatoid arthritis
10. [10]Wakelkamp IM, Gerding MN, Van Der Meer JW, Prummel MF, Wiersinga WM. Both Th1- and Th2-derived cytokines in serum are elevated in Graves' ophthalmopathy
11. Douglas RS, Kahaly GJ, Patel A, Sile S, Thompson EH, Perdok R, et al. Teprotumumab for the treatment of active thyroid eye disease. *N Engl J Med*. 2020 Jan; 382(4): 341- 52.
12. Terwee CB, Dekker FW, Mourits MP, Gerding MN, Baldeschi L, Kalmann R, et al. Interpretation and validity of changes in scores on the Graves' ophthalmopathy quality of life questionnaire (GO-QOL) after different treatments. *Clin Endocrinol*. 2001 Mar; 54(3): 391-8.
13. Smith TJ, Kahaly GJ, Ezra DG, Fleming JC, Dailey RA, Tang RA, et al. Teprotumumab for thyroid-associated ophthalmopathy. *N Engl J Med*. 2017 May; 376(18): 1748-61.
14. Tsui S, Naik V, Hoa N, Hwang CJ, Afifiyan NF, Sinha Hikim A, Gianoukakis AG, Douglas RS, Smith TJ. Evidence for an association between thyroid-stimulating hormone

- and insulin-like growth factor 1 receptors: a tale of two antigens implicated in Graves' disease. *J Immunol.* 2008; 181: 4397–405.
15. Krieger CC, Neumann S, Marcus-Samuels B, Gershengorn MC. TSHR/IGF-1R cross-talk, not IGF-1R stimulating antibodies, mediates Graves' ophthalmopathy pathogenesis. *Thyroid.* 2017 May; 27(5): 746–7.
 16. Minich WB, Dehina N, Welsink T, Schwiebert C, Morgenthaler NG, Köhrle J, et al. Autoantibodies to the IGF1 receptor in Graves' orbitopathy. *J Clin Endocrinol Metab.* 2013 Feb; 98(2): 752–60.
 17. Varewijck AJ, Boelen A, Lamberts SW, Fliers E, Hofland LJ, Wiersinga WM, et al. Circulating IgGs may modulate IGF-I receptor stimulating activity in a subset of patients with Graves' ophthalmopathy. *J Clin Endocrinol Metab.* 2013 Feb; 98(2): 769–76
 18. Gianoukakis AG, Douglas RS, King CS, Cruikshank WW, Smith TJ. Immunoglobulin G from patients with Graves' disease induces interleukin-16 and RANTES expression in cultured human thyrocytes: a putative mechanism for T-cell infiltration of the thyroid in autoimmune disease. *Endocrinology.* 2006 Apr; 147(4): 1941–9.
 19. Smith TJ, Hoa N. Immunoglobulins from patients with Graves' disease induce hyaluronan synthesis in their orbital fibroblasts through the self-antigen, insulin-like growth factor-I receptor. *J Clin Endocrinol Metab.* 2004 Oct; 89(10): 5076–80.
 20. Pritchard J, Horst N, Cruikshank W, Smith TJ. Igs from patients with Graves' disease induce the expression of T cell chemoattractants in their fibroblasts. *J Immunol.* 2002; 168: 942–50.
 21. Fernando R, Adkins SJ, Smith TJ. Slit2 may underlie divergent induction by thyrotropin of IL-23 and IL-12 in human fibrocytes. *J Immunol.* 2020; 204: 1724–1735.
 22. Wakelkamp IM, Bakker O, Baldeschi L, Wiersinga WM, Prummel MF. TSH-R expression and cytokine profile in orbital tissue of active vs. inactive Graves' ophthalmopathy patients. *Clin Endocrinol (Oxf).* 2003 Mar; 58(3): 280–7.
 23. Durrani OM, Reuser TQ, Murray PI. Infliximab: a novel treatment for sight-threatening thyroid associated ophthalmopathy. *Orbit.* 2005 Jun; 24(2): 117–9.
 24. Paridaens D, van den Bosch WA, van der Loos TL, Krenning EP, van Hagen PM. The effect of etanercept on Graves' ophthalmopathy: a pilot study. *Eye (Lond).* 2005 Dec; 19(12): 1286–9.
 25. Perez-Moreiras JV, Gomez-Reino JJ, Maneiro JR, Perez-Pampin E, Romo Lopez A, Rodríguez Alvarez FM, et al.; Tocilizumab in Graves Orbitopathy Study Group. Efficacy of tocilizumab in patients with moderate-to-severe corticosteroid-resistant Graves orbitopathy: a randomized clinical

- trial. *Am J Ophthalmol.* 2018 Nov; 195: 181–90.
26. Kaleko M, Rutter WJ, Miller AD. Overexpression of the human insulinlike growth factor I receptor promotes ligand-dependent neoplastic transformation. *Mol Cell Biol.* 1990 Feb; 10(2): 464–73.
27. Mauro L, Naimo GD, Ricchio E, Panno ML, Andò S. Cross-talk between adiponectin and IGF-IR in breast cancer. *Front Oncol.* 2015 Jul; 5: 157.
28. Qu X, Wu Z, Dong W, Zhang T, Wang L, Pang Z, et al. Update of IGF-1 receptor inhibitor (ganitumab, dalotuzumab, cixutumumab, teprotumumab and figitumumab) effects on cancer therapy. *Oncotarget.* 2017 Apr; 8(17): 29501–18.
29. Smith TJ. Insulin-like growth factor-I regulation of immune function: a potential therapeutic target in autoimmune diseases? *Pharmacol Rev.* 2010 Jun; 62(2): 199–236.
30. Weightman DR, Perros P, Sherif IH, KendallTaylor P. Autoantibodies to IGF-1 binding sites in thyroid associated ophthalmopathy. *Autoimmunity.* 1993; 16(4): 251–7.
31. Tramontano D, Cushing GW, Moses AC, Ingbar SH. Insulin-like growth factor-I stimulates the growth of rat thyroid cells in culture and synergizes the stimulation of DNA synthesis induced by TSH and Graves'-IgG. *Endocrinology.* 1986 Aug; 119(2): 940–2.
32. Mester T, Raychaudhuri N, Gillespie EF, Chen H, Smith TJ, Douglas RS. CD40 expression in fibrocytes is induced by TSH: potential synergistic immune activation. *PLoS One.* 2016 Sep; 11(9):e0162994.
33. Li B, Smith TJ. PI3K/AKT pathway mediates induction of IL-1RA by TSH in fibrocytes: modulation by PTEN. *J Clin Endocrinol Metab.* 2014 Sep; 99(9): 3363–72.
34. Raychaudhuri N, Fernando R, Smith TJ. Thyrotropin regulates IL-6 expression in CD34+ fibrocytes: clear delineation of its cAMP-independent actions. *PLoS One.* 2013 Sep; 8(9):e75100.
35. Pritchard J, Han R, Horst N, Cruikshank WW, Smith TJ. Immunoglobulin activation of T cell chemoattractant expression in fibroblasts from patients with Graves' disease is mediated through the insulin-like growth factor I receptor pathway. *J Immunol.* 2003; 170: 6348–54.
36. Heufelder AE, Bahn RS. Detection and localization of cytokine immunoreactivity in retro-ocular connective tissue in Graves' ophthalmopathy. *Eur J Clin Invest.* 1993 Jan; 23(1): 10–7.
37. Wakelkamp IM, Gerding MN, Van Der Meer JW, Prummel MF, Wiersinga WM. Both Th1- and Th2-derived cytokines in serum are elevated in Graves' ophthalmopathy. *Clin Exp Immunol.* 2000 Sep; 121(3): 453–7.